








## A New Method to Harvest the Sural Nerve Graft

Hakan Cinal<sup>1</sup> , Ensar Zafer Barin<sup>1</sup> , Murat Kara<sup>1</sup> , Harun Karaduman<sup>1</sup> , Ihtisam Zafer Cengiz<sup>1</sup> ,  
Onder Tan<sup>2</sup> , Elif Demirci<sup>3</sup> 



**Cite this article as:** Cinal H, Barin EZ, Kara M, et al. A New Method to Harvest the Sural Nerve Graft. *Eurasian J Med* 2020; 52(1): 12-5.

<sup>1</sup>Department of Plastic Reconstructive and Aesthetic Surgery, Atatürk University School of Medicine, Erzurum, Turkey

<sup>2</sup>Department of Plastic Reconstructive and Aesthetic Surgery, Gaziosmanpaşa Medical Park Hospital, İstanbul, Turkey

<sup>3</sup>Department of Pathology, Atatürk University School of Medicine, Erzurum, Turkey

Received: March 27, 2019

Accepted: May 24, 2019

Correspondence to: Hakan Cinal  
E-mail: mdcinal@gmail.com

DOI 10.5152/eurasianjmed.2019.19102



Content of this journal is licensed under a Creative Commons Attribution 4.0 International License.

### ABSTRACT

**Objective:** In this study, we developed a novel technique to harvest the sural nerve using the mini incisions and the carpal tunnel dilators.

**Materials and Methods:** The technique was applied to the 29 sides on 27 patients (24 men and 3 women). The mean age was 27.1 years (range 9-51). The diagnoses were soft tissue traumas in 23 cases, fracture in 2 cases, and previous complicated operation in 2 cases. The harmful effects of harvest procedure on the sural nerve graft were assessed double-blind histopathologically and compared with control group.

**Results:** All the nerve grafts were successfully harvested with no macroscopic damage to the sural nerve graft. There was no statistically significant difference between the histopathologic scores of the distal and proximal nerve segments ( $p>0.05$ ). The average follow-up time was 17 months (range 8-46). In the postoperative period, no complication such as massive bleeding/hematoma, wound infection, skin necrosis, painful neuroma formation, or prolonged calf tenderness was observed. In all cases, there were inconspicuous scars.

**Conclusion:** The method seems safe and has no damage on the nerve graft histopathologically. We believe that this technique may be used in future.

**Keywords:** carpal tunnel dilator; harvest; nerve; sural

### Introduction

The sural nerve is a pure sensory cutaneous nerve that innervates the posterolateral aspect of the leg and foot. It divides into medial and lateral branches in 18%–100% in frequency, respectively [1]. In peripheral nerve surgery, the sural nerve graft is the most often used [2] donor nerve with its advantages like easy dissection, adequate length, and calibration [3, 4].

Several methods, such as open, stair-step or stepladder and endoscopic techniques, have been introduced in the literature to harvest the sural nerve [5, 6]. All these techniques have some considerable disadvantages that may limit their use and popularity. In the classic technique, the nerve is harvested through a long incision that may lead to a conspicuous scar. This is a major drawback of this method. Therefore, we need a new sural nerve harvest technique with minimal drawbacks.

In this study, we developed a novel harvest technique for the sural nerve using mini incisions and the carpal tunnel dilators. After harvesting, nerve graft was also scored histopathologically to prove the safety of method on nerve graft. This is the first study in the literature to evaluate sural nerve graft sound histologically after harvesting.

### Materials and Methods

The same senior surgeon performed all the operations. The technique was applied to the 29 sides on 27 patients (24 men and 3 women). The mean age was 27.1 years (range 9-51). The diagnoses were soft tissue traumas (sharp, blunt, crush) in 23 cases, fracture in 2 cases, and previous complicated operation in 2 cases.

The mean length and cable numbers of the harvested nerves were 20.9 cm and 3.03, respectively. The mean operation time was 17 min. Recipient nerves were median nerves in 13 cases,

ulnar nerves in 12 cases, radial nerves in 6 cases, facial nerves in 2 cases, peroneal nerves in 2 cases, and sciatic nerve in 1 case. To investigate possible damage of the harvesting technique on the sural nerve, nerve segments of 1 cm each were divided from the most distal and proximal sides of the nerve grafts in 11 patients randomly and evaluated histopathologically. In our study, we used a double-blind histopathological assessment of the nerve grafts. In this method, we provided the most distal segment of the sural nerve graft as a control at the beginning of the surgical procedure, which was never affected from the traction force.

### Histopathological Analysis

After resection of the sural nerve graft, the tissue samples were fixed in 10% formalin for at least 24 h and embedded in paraffin blocks. Sections of 5 µm were obtained from proximal and distal ends of samples using a microtome and placed on glass slides. Tissue samples were stained with hematoxylin & eosin. The same two pathologists examined the sections under a light microscope (Zeiss Scope.A1) in double-blind fashion. Sural nerves samples were histopathologically examined in terms of inflammation, stromal edema, nuclear hyperchromasia, cytoplasmic eosinophilia, and scored as follows: (Figure 1)

Grade 0: none  
Grade 1: mild  
Grade 2: intermediate  
Grade 3: severe

### Statistical Analysis

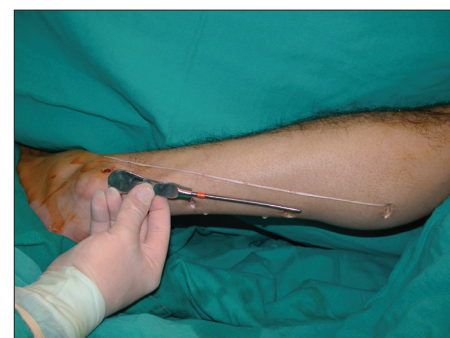The histopathological scores were statistically analyzed. The Mann–Whitney U test was used for statistical comparisons.  $p < 0.05$  was considered statistically significant.

### Surgical Technique

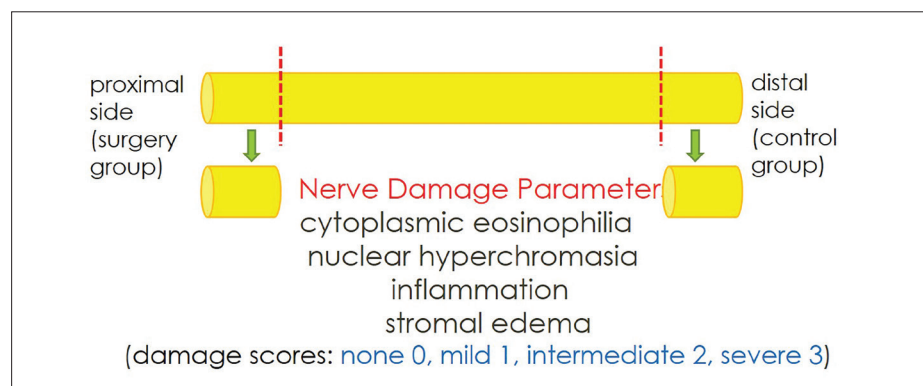
We harvested the main (medial) branch of sural nerve graft from distal to proximal side direction through several mini transverse incisions of 1-2 cm. After the nerve was dissected and suspended with a silastic tape, its segment underneath the skin was fully and circumferentially released by using the carpal tunnel dilators (Figure 2). The distal end was divided, and the nerve was then pulled out through the proximal incision (Figure 3). This process was continued until we obtained the desired length of the nerve graft (Figures 4, 5). When the lateral branch was encountered, medial main branch could not be easily pulled out. In this case, the lateral branch was divided through the same or supplement mini skin incision to complete the procedure (Figure 6).

### Results

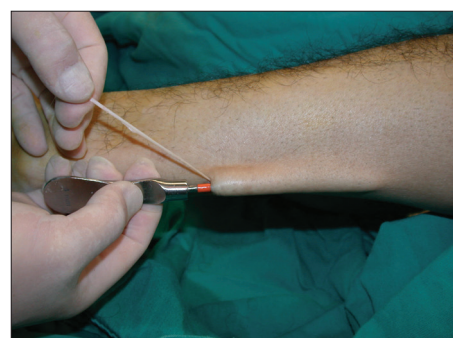All the nerve grafts were successfully harvested with no macroscopic damage to the sural nerve graft. Histopathological assessment results of the nerve grafts are given at Table 1. There was no statistically significant difference between the histopathologic scores of the distal and proximal nerve segments ( $p > 0.05$ ). The average follow-up time was 17 months (range 8-46). In the postoperative period, no complication such as massive bleeding/hematoma, wound infection, skin necrosis, painful neuroma formation, prolonged calf tenderness was observed in any of the patients. In all cases, there were inconspicuous scars.



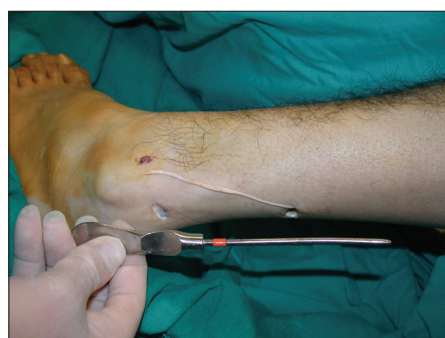**Figure 4.** This process was continued until the desired length of the nerve graft was obtained.



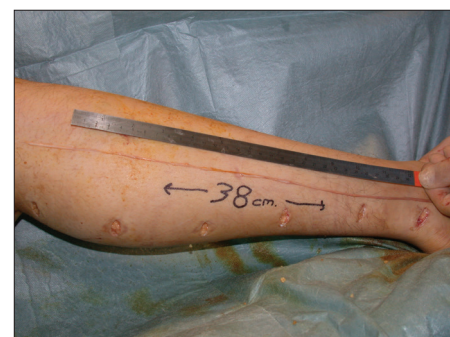
**Figure 1.** The parameters of histopathologic evaluation that were applied in 11 random patients.



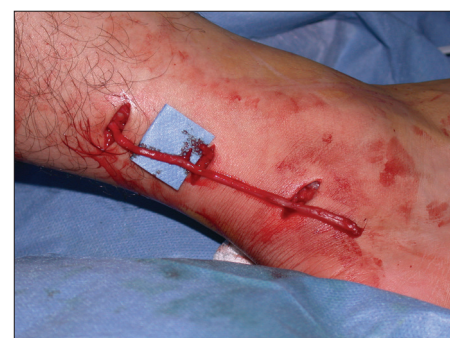**Figure 2.** The sural nerve segment underneath the skin was fully and circumferentially released using the carpal tunnel dilators.



**Figure 3.** The distal end was divided, and the nerve was then pulled out through the proximal incision.



**Figure 5.** The sural nerve graft of 38 cm could be harvested with this technique.



**Figure 6.** When the lateral branch was encountered, it was divided through supplement mini skin incision to complete the procedure.

**Table 1.** Histopathological assessment results of the sural nerve grafts

Case	Cytoplasmic eosinophilia		Nuclear hyperchromasia		Inflammation		Stromal edema	
	Proximal	Distal	Proximal	Distal	Proximal	Distal	Proximal	Distal
1	0	0	0	1	0	0	1	0
2	0	0	0	0	0	0	3	3
3	0	0	2	3	2	3	2	1
4	0	0	1	1	1	1	1	0
5	0	0	2	0	2	0	2	2
6	0	0	0	0	0	0	1	2
7	0	0	3	2	3	2	1	1
8	0	0	2	1	2	0	0	3
9	0	0	3	1	3	1	0	0
10	0	0	0	2	0	2	3	2
11	0	0	3	1	3	1	3	2
p	1.0		0.51		0.31		0.86	

## Discussion

The sural nerve is widely used as an autologous nerve graft for peripheral nerve surgery because it has some considerable advantages such as easy and quick harvest, adequate length, straight course with minimal branching, appropriate calibration, high number of fascicular groups, and low donor site morbidity [3, 4].

In classical open technique, the nerve graft is removed through a long skin incision from distal to proximal side of the leg. With this incision, the operation can be easily performed with maximum exposure and minimal risk of nerve graft damage. However, this method may lead to unsightly stocking-seam scar as a considerable drawback [4].

In limited open techniques to harvest the sural nerve using the tendon stripper, vein stripper, and nerve stripper [7, 8], harvest can be made through shorter incisions in the manner of stepladder. Kim et al. [7] used the sural nerve as a genitofemoral nerve graft after radical retropubic prostatectomy. In their series, 12 men underwent nerve harvesting using a tendon stripper. However, they subjectively assessed the postoperative functions of sural nerve graft by using patient questionnaire method. Jaroszynski et al. [9] harvested the sural nerve by using a tendon stripper at the 12 above-knee amputation specimens. They reported some histological injury on the epineurium of sural nerve graft with tendon stripping method. The perineurium, however, remained uninjured in this study. This was not a comparable study that was unable to present any significant difference between the surgical and control groups. Hassanpour et al. [8] harvested the sural nerve graft using the nerve stripper. Although the authors

reported no damage on the sural nerve with this technique, the neural damage was evaluated by Tinel's Sign as a subjective test in this study. In harvesting procedures with strippers, nerve graft damage may occur due to undue traction to the graft [10], and it should be proved with objective tests.

Spinks et al. [11] harvested the sural nerve grafts for three pediatric patients undergoing brachial plexus surgery, after demonstrating the endoscopic technique on two adult cadaver legs. To evaluate the graft quality, the grafts were examined with direct vision under the operative microscope, but there were no specimens for histology. Capek et al. [12, 13] reported a large series of 200 infants in which the sural nerve graft was harvested via the endoscopic technique. All nerve grafts were intraoperatively examined under the operating microscope. No visible nerve graft injuries were noted during the harvesting procedure based on the microscopic findings. Koh et al. [14] used balloon dissection for endoscopic harvest of the sural nerve for facial nerve reconstruction following parotidectomy and neck dissection in one case. Lin et al. [6] reported 15 patients with posttraumatic upper limb nerve defects of the ulnar, median, or posterior interosseous nerves who underwent reconstruction with endoscopically harvested sural nerve. The British Medical Research Council Scales (BMRCs) did postoperative sural nerve assessments in this series. However, there are many factors that affect success of the surgery, such as coaptation technique, location of the repaired nerve, postoperative complications, general health status, and co-morbidities of the patient, as well as graft harvest technique. Therefore, postoperative clinical findings as

in the BMRCs were not correlated with success of the nerve graft harvest techniques alone. Minimal incision seems to be the main advantage of this technique. However, the endoscopic technique has some disadvantages such as need for sophisticated and expensive instruments, prolonged operative time, and long learning curve. Moreover in all studies of the endoscopic technique, success of the sural nerve harvest was only assessed clinically, but not histologically.

In evaluation of harvest techniques of the sural nerve graft, intraoperative visual inspection cannot be adequate to identify the damaged nerves. Nerves that appear normal on gross inspection may show obvious disruption of the perineurium under microscopy [9]. We also believe that all subjective tests remain inadequate in evaluation of the nerve damage. Thus, we used a double-blind histopathological assessment of the nerve grafts in our study. In this method, we provided the most distal segment of the sural nerve graft as a control at the beginning of the surgical procedure, which was never affected from the traction force. At the end of the surgery, we obtained the most proximal segment of the nerve graft as a study group, which was most possible to be affected from the traction force.

In conclusion, our novel technique is easy to learn and perform, needs minimal incisions, does not require a sophisticated surgical device and long operation time, and leads to less donor site morbidity. The method also seems to be safe and has no damage on the nerve graft histopathologically. We believe that this technique may be used in future with all these advantages.

**Ethics Committee Approval:** Ethics committee approval was received for this study from the ethics committee of

**Informed Consent:** XX

**Peer-review:** Externally peer-reviewed.

**Author Contributions:** Concept – H.C., E.Z.B., O.T.; Design – H.C., E.Z.B., M.K., H.K.; Supervision – H.C., E.Z.B.; Resources – H.C., E.Z.B., M.K.; Materials – H.C., E.Z.B., H.K.; Data Collection and/or Processing – H.C., M.K., I.Z.C.; Analysis and/or Interpretation – H.C., E.D.; Literature Search – H.C., E.Z.B., M.K., H.K.; Writing Manuscript – H.C., E.Z.B., M.K., H.K.; Critical Review – H.C., O.T., E.Z.B.

**Conflict of Interest:** The authors have no conflicts of interest to declare.

**Financial Disclosure:** The authors declared that this study has received no financial support.

## References

1. Park HD, Kwak HH, Hu KS, et al. Topographic and histologic characteristics of the sural nerve for use in nerve grafting. *J Craniofac Surg* 2007; 18: 1434-8. [\[CrossRef\]](#)
2. Riedl O, Koemuercue F, Marker M, et al. Sural nerve harvesting beyond the popliteal region allows a significant gain of donor nerve graft length. *Plast Reconstr Surg* 2008; 122: 798-805. [\[CrossRef\]](#)
3. de Moura W, Gilbert A. Surgical anatomy of the sural nerve. *J Reconstr Microsurg* 1984; 1: 31-9. [\[CrossRef\]](#)
4. Coert JH, Dellon AL. Clinical implications of the surgical anatomy of the sural nerve. *Plast Reconstr Surg* 1994; 94: 850-5. [\[CrossRef\]](#)
5. Hankin FM, Jaeger SH, Beddings A. Autogenous sural nerve grafts: a harvesting technique. *Orthopedics* 1985; 8: 1160-1.
6. Lin CH, Mardini S, Levin SL, et al. Endoscopically assisted sural nerve harvest for upper extremity posttraumatic nerve defects: an evaluation of functional outcomes. *Plast Reconstr Surg* 2007; 119: 616-26. [\[CrossRef\]](#)
7. Kim ED, Seo JT. Minimally invasive technique for sural nerve harvesting: technical description and follow-up. *Urology* 2001; 57: 921-4. [\[CrossRef\]](#)
8. Hassanpour E, Yavari M, Karbalaieikhani A, et al. Nerve stripper-assisted sural nerve harvest. *J Neurol Surg A Cent Eur Neurosurg* 2014; 75: 161-4. [\[CrossRef\]](#)
9. Jaroszynski G, Johnston GH. Harvesting of the sural nerve with a tendon stripper. *Microsurgery* 1996; 17: 217-20.
10. Wessberg GA. Atraumatic harvesting of the sural nerve. *J Oral Maxillofac Surg* 1985; 43: 237. [\[CrossRef\]](#)
11. Spinks TJ, Adelson PD. Pediatric sural nerve harvest: a fully endoscopic technique. *Neurosurgery* 2009; 64: 360-3; discussion 363-4. [\[CrossRef\]](#)
12. Capek L, Clarke HM. Endoscopically assisted sural nerve harvest in infants. *Semin Plast Surg* 2008; 22: 25-8. [\[CrossRef\]](#)
13. Capek L, Clarke HM, Zuker RM. Endoscopic sural nerve harvest in the pediatric patient. *Plast Reconstr Surg* 1996; 98: 884-8. [\[CrossRef\]](#)
14. Koh KS, Park S. Endoscopic harvest of sural nerve graft with balloon dissection. *Plast Reconstr Surg* 1998; 101: 810-12. [\[CrossRef\]](#)